



Investigation and management of dry eyes in Sjögren's Disease

This article is based on notes taken during a presentation by Mr Andrew Coombes, a Consultant Ophthalmologist at Barts, at the BSSA Medical Meeting, 2015, Cognitive difficulties.

He reminded us that Henrik Sjögren's himself was an ophthalmologist and first described the condition which bears his name in the 1930's.

Mr Coombes described the normal eye anatomy (see picture). The large lacrimal (tear) gland in the upper outer eye socket produces 'reflex' tears (usually provoked by emotion or physical discomfort) whilst most background tears are produced by the smaller glands on the eye surface.

Dryness of eyes is multifactorial and in most cases a combination of increased evaporative loss, aqueous deficiency, and meibomian (oil) gland deficiency.

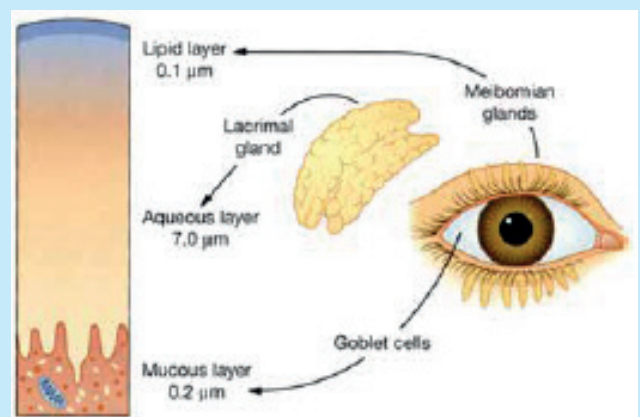
Symptoms include – dryness, gritty and painful eyes.

Fluorescein dye (or lissamine green) can help the ophthalmologist assess the surface dryness and its severity.

Marginal tear film is the meniscus of tears that normally collects in the lower eyelid. This is absent or reduced in Sjögren's. Tear 'break up time' (BUT) is the amount of time it takes for the surface layer of tears to dissipate after a blink and in Sjögren's this is usually reduced to less than 10 seconds.

Schirmer's test is a simple test used to assess dryness in the clinic setting. A piece of filter paper is placed in the lower eyelid and the amount of wetting over a 5 minute period is measured. The standard test is performed without local anaesthetic. A modified Schirmer's test with local anaesthetic is called the 'Jones test'.

Corneal (eye surface) sensation is altered in patients with Sjögren's Disease. Over time the corneal surface may become less sensitive and this can lead to a further



reduction in tear production because of reduced 'feedback' from the eye surface. Other tests used in research work include – impression cytology, osmolality, confocal microscopy etc.

Treatment strategies include the replacement of tears, reduction of evaporation, stimulation of tears and meibomian secretions.

For tear replacement multiple products are available. How do you decide which one you should use? It is a good idea to avoid preservatives (especially if frequent eye drop use). The viscosity or 'thickness' of the drop is usually down to personal preference. The cost of the product is

an issue and in some the design of the delivery system is key.

Acetylcysteine (ilube) is useful for filaments on the surface of the eye. In some specialist centres autologous serum eye drops are available for patients with severe dry eye that has not responded to other treatments.

Oral pilocarpine has been shown to improve tear production and can be useful if patients are able to tolerate it (Papas et al 2004).

Disease modification – local and systemic treatments may influence the underlying disease and improve tear secretion in some patients.

Local (topical) treatments include cyclosporine eye drops (restasis and Moorfields) and cyclosporine ointments. From July a new licensed cyclosporine eye drop will be available in the UK and is to be marketed as Ikervis. These products can only be initiated by an ophthalmologist.

Tacrolimus containing drops – research evidence shows some benefit but not yet commercially available.

Tear retention/reduction of evaporation – modify environment (humidity, air conditioning, wrap round glasses, PC use).

Punctal occlusion – use temporary plugs first. If helpful you can occlude all 4 puncta.

Blepharitis – inflammation of the eyelid. Both anterior (eyelashes) and posterior (Meibomian glands) inflammation is observed. Treatment includes daily bathing of eyelids with warm water compresses and using cotton buds. Adding a little baby shampoo or sodium bicarbonate to the bathing solution will help remove crusts and debris.

Meibomian gland disease reduces the oily top layer and exacerbates evaporative loss.

Topical antibiotics are sometimes used in severe exacerbations of blepharitis (with topical fucithalamic or similar) or oral doxycycline in a few cases.

Omega 3 supplementation has been shown to help tear secretion (Bhargava et al 2013).

Contact lenses are relatively contraindicated because of increased risk of infection and discomfort. Glasses are better as they help reduce evaporative loss of tears!

Laser refractive surgery is contraindicated as it worsens dryness.

Become a member

To become a member of Sjögren's UK and enjoy all the benefits we offer, fill in the membership form on our website www.sjogrenuk.org

UK membership £30.00 per year

Overseas membership £35.00 per year

Sjögren's Disease is the UK's second most common autoimmune rheumatic disease, yet the condition remains under recognised and frequently under treated. It does not command a high profile within the medical profession and the general public is largely unaware of the problems faced by sufferers. In reality, Sjögren's Disease is a debilitating, distressing and miserable condition.

